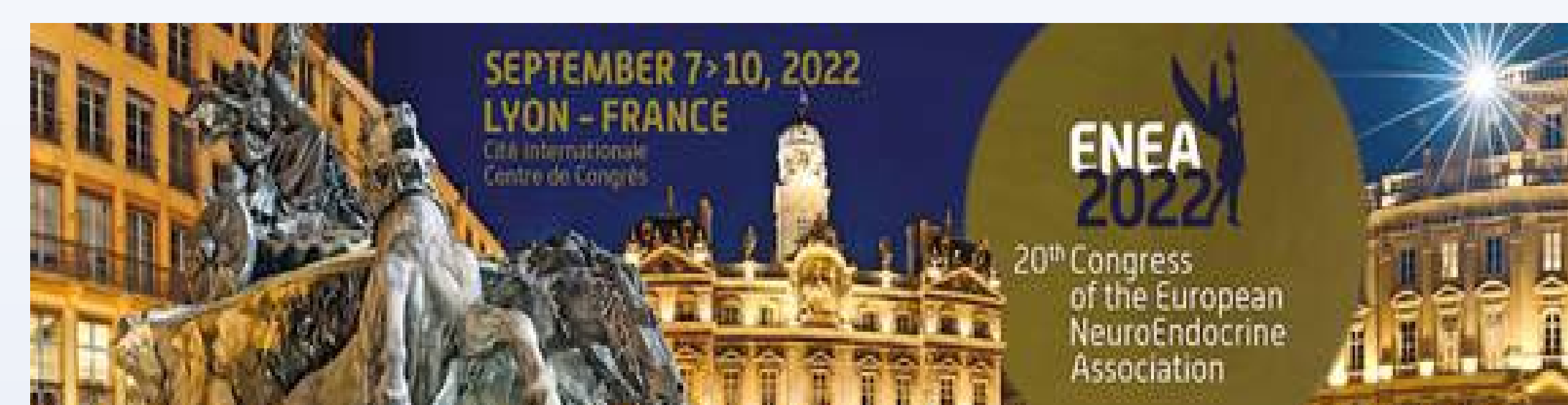

Gonadotroph Adenomas. A Single-Center Study of 112 cases.

M. Solovey^a, M. Guk^b, O. Danevych^b, A. Chukov^b

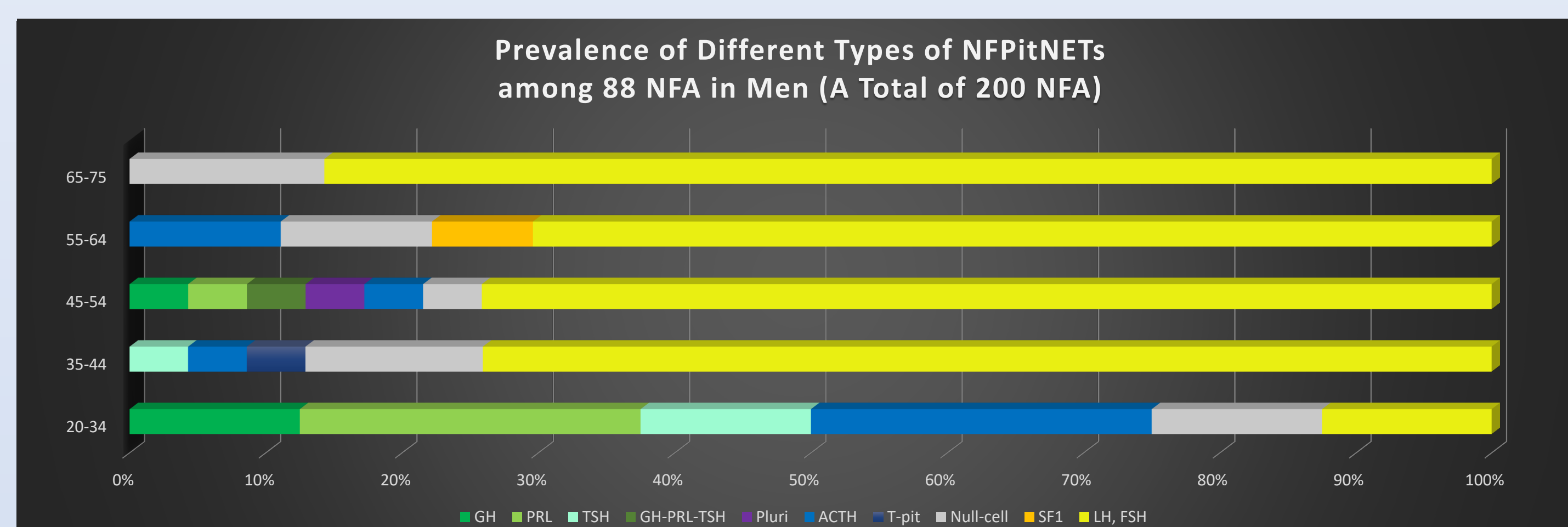
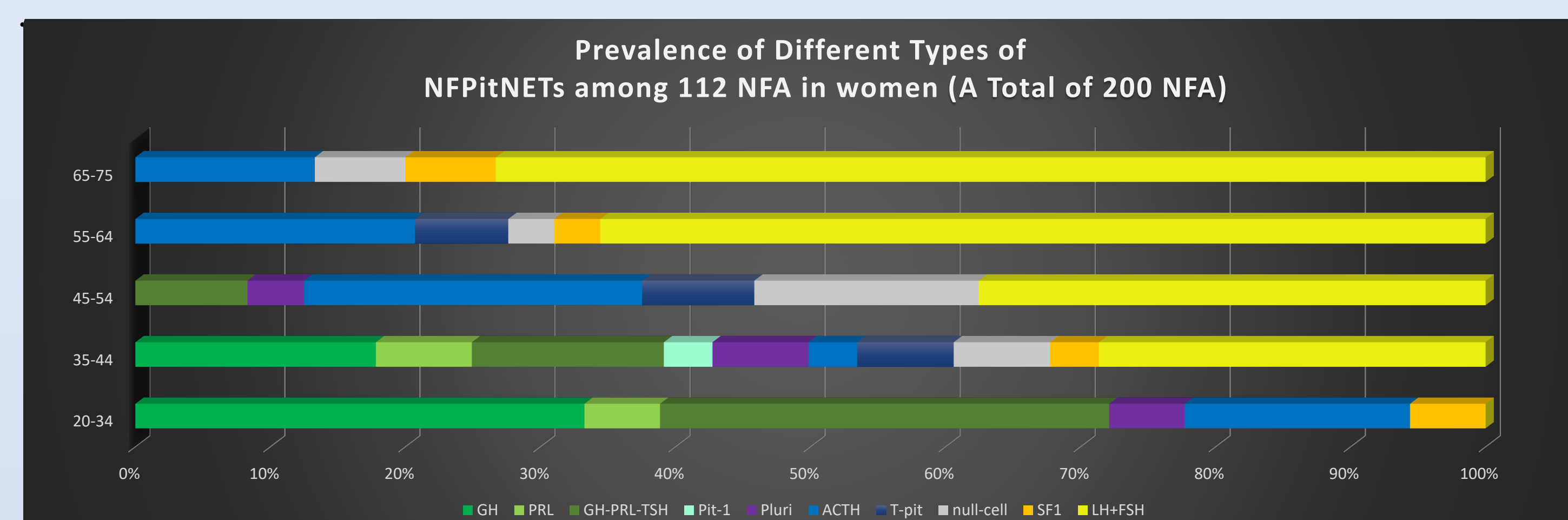
^a Komisarenko Endocrinology and Metabolism Institut, Romodanov Neurosurgery Institute, Kyiv, UKRAINE ; ^b Romodanov Neurosurgery Institute, Kyiv, UKRAINE



Background. Gonadotroph adenomas (GA) are the most common type of clinically nonfunctioning pituitary adenomas (NFAs), totally silent in the most cases. Clinical presentation of the gonadotroph adenoma depends on its biological behaviour. There are few data regarding the age and sex prevalence of gonadotroph adenomas and clinical data correlations.

Objective. To discover age and sex prevalence of gonadotroph adenomas and the differences in clinical presentation according to the immunohistochemical staining.

Materials and Methods. The study includes 112 cases of clinically nonfunctioning pituitary adenomas removed in our center via transnasal transsphenoidal endoscopic approach with positive immunohistochemical staining for gonadotropins and/or steroidogenic factor 1 (SF1). All patients (50 women and 62 men) have been divided into five age groups: 20-34 (A) years old, 35-44 (B) years old, 45-54 (C) years old, 55-64 (D) years old, 65-75 (E) years old. Peculiarities of immunohistochemical profile have been statistically analyzed in those age groups. Clinical presentation, imaging, laboratory hormonal data and immunohistochemical staining features have been analyzed in such groups: LH-positive, FSH-positive, LH-FSH-positive, LH-FSH-negative but SF1-positive, accordingly to the Ki-67 proliferative index.



Results. The prevalence of silent GA have appeared to be increased with age with predominant proportion in groups D-E in women and groups B-E in men with more frequent incidence in men.

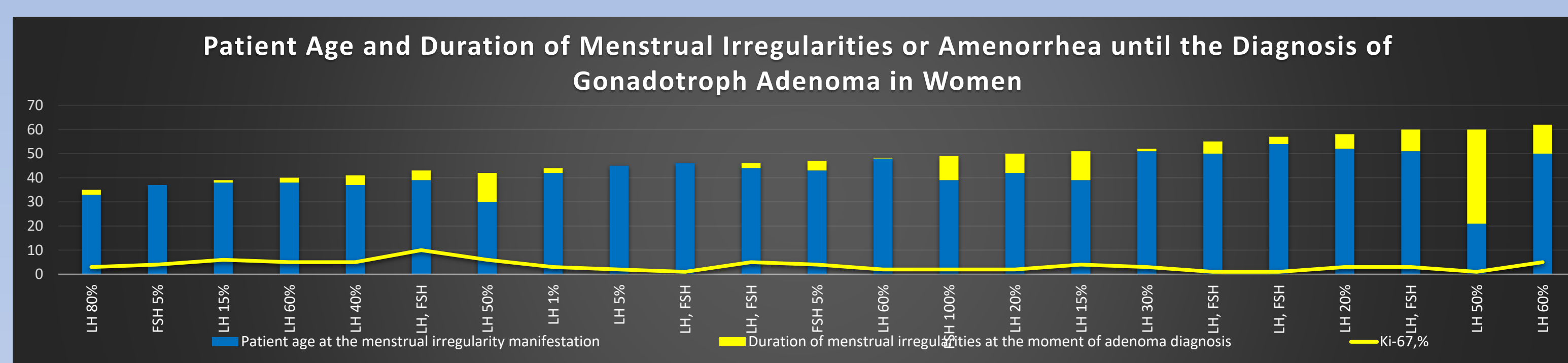
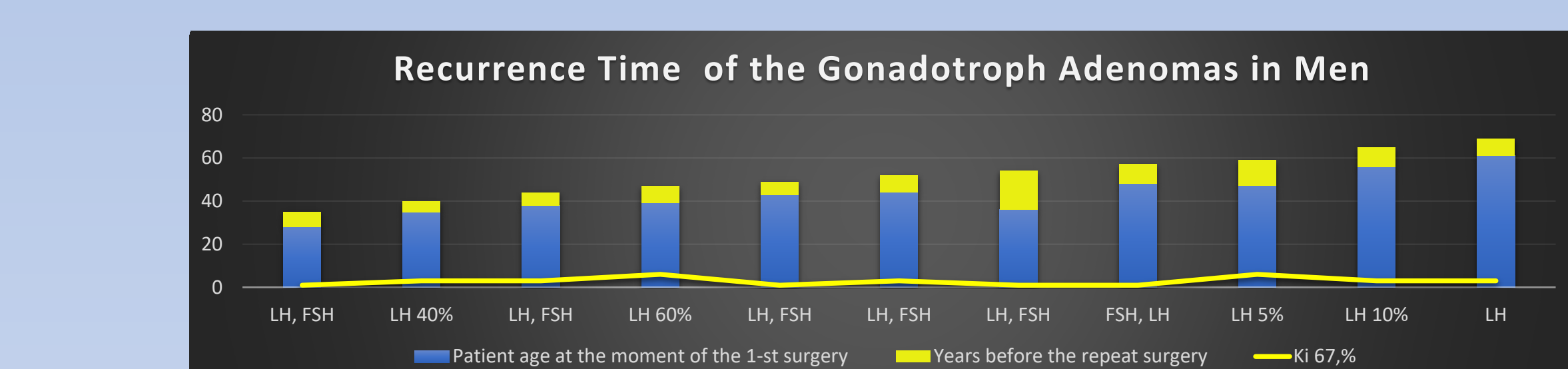
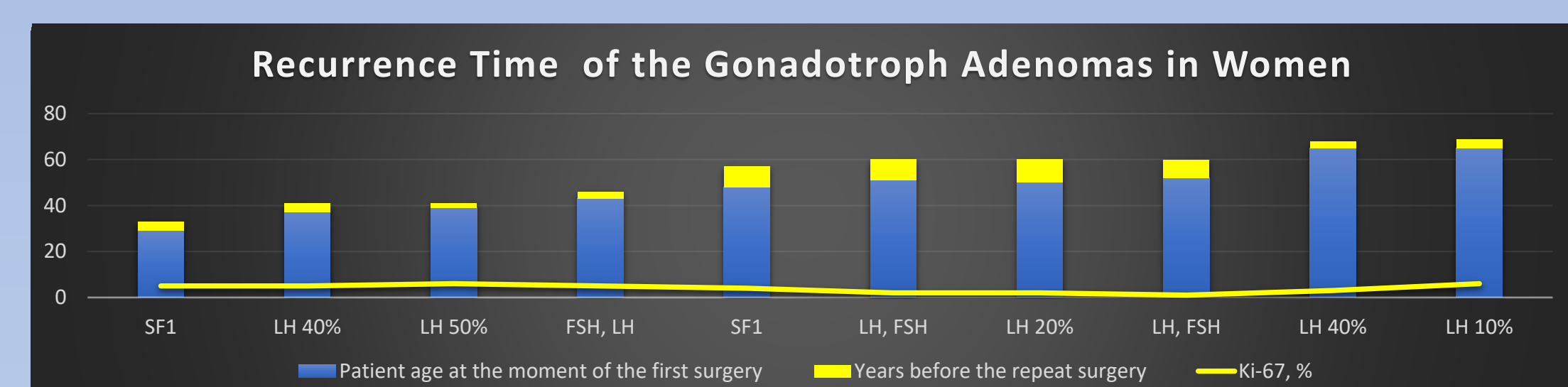
Gonadotroph adenomas have shown great variety of imaging and clinical presentation. The majority of GA were immuno-positive for LH or the combination of LH-FSH with LH predominance. There were no correlations between Ki-67 index and invasiveness of GA, but we have noticed many similarities in clinical presentation accordingly to the immunohistochemical feature.

The incidence of panhypopituitarism and visual disturbances was the most frequent in men with LH-positive adenomas which could be explained by the time of tumor growth, its extension and inefficient hormonal activity. The time of the recurrence of GA have appeared to be increased with age in women and with negative Ki-67 correlation. There was no correlation between Ki-67 index and time of the recurrence of GA in men. The evidences of hormonal activity of GA there were retrospectively revealed in some patients. We have hypothesized that hormonal activity of GA may decrease with patient age. We suppose that low level of DHEA-s in combination with suppressed LH level without evidence of hypopituitarism in women with the history of amenorrhea may be indicative for premature ovarian failure.

Immuno-staining, men	Ki-67, %	n	Patient Age	Invasive	Giant	Cystic	Extension	Repeat surgery	Apoplexy	Visual Disturbances	Panhypopituitarism	PRL	Functional	LH/FSH	Symptoms
FSH, FSH-LH	1	4	20-52	-	1 (25%)	2 (50%)	suprasellar	-	-	3 (75%)	1 (25%)	Elevated	-	0,19-0,26	ED, lost weight, (obesity, hypothyroidism – in cystic)
FSH, FSH-LH	2-4	4	37-63	2 (50%)	-	-	suprasellar, cavernous sinus	-	2 (50%)	4 (100%)	2 (50%)	N	1	0,5	ED, flushes, sweating, cryptorchidism
SF1	2-5	2	57-60	1 (50%)	-	-	1 occlusive hydrocephalus	-	-	1 (50%)	partial	Elevated	-	1,2	ED, flushes, lost weight, weakness
LH, FSH	1	8	35-61	7 (88%)	4 (50%)	-	supra-ante-infra-CS, 1 – to the third ventricle	3 (37,5%)	-	5 (62%)	1 (12,5%)	N, 1-elev.	2	0,4	Flushes, ED, weakness, in 1 patient – obesity (GH deficiency), In 1 patient- gynecomastia, nodular goiter
LH, FSH	2-3	10	44-63	6 (60%)	4 (40%)	-	CS, suprasellar cisterns, third ventricle	2 (20%)	1 (10%)	6 (60%)	2 (20%)	N	-	0,2-0,5	ED, sweating, arterial hypertension, 1 nodular goiter, 1 elevated IGF-1
LH, FSH	4	3	44-62	-	-	-	suprasellar	-	-	1 (33%)	1 (33%)	Elevated	-	0,4	ED, arterial hypertension, diabetes mellitus
LH, FSH	6	1	58	+	+	-	third ventricle	-	-	+	+	N	-	0,5	ED, obesity, arterial hypertension, drowsiness

Immuno-staining, men	Ki-67, %	n	Patient Age	Invasive	Giant	Cystic	Extension	Repeat surgery	Apoplexy	Visual Disturbances	Panhypopituitarism	PRL	Functional	LH/FSH	Symptoms
LH	1	3	38-53	-	-	-	supra-infra	-	1 (33%)	100%	partial	+/-	+/-	0,4-0,5	ED, sweating, weight lost, arterial hypertension
LH	2	4	53-64	2 (50%)	-	-	suprasellar, CS	1 (25%)	1 (25%)	100%	2 (50%)	elevated	-	0,9-1,1	ED, headache, weakness
LH	3-5	15	38-78	3 (20%)	2 (13%)	3 (20%)	mainly supra-, CS	2 (13%)	1 (7%)	100%	7 (47%)	+/-	-	0,4-0,9	ED, flushes, arterial hypertension, atherosclerosis, osteoporosis, 2 nodular goiter, 1 rectum cancer
LH	6	3	47-66	100%	1 (33%)	-	Infra-supra, third ventricle	2 (67%)	1 (33%)	100%	100%	N	-	0,4	related to tumor mass effect
LH	8-10	4	39-56	2 (50%)	-	-	Supra-infra-CS	-	-	3 (75%)	Partial (hypothyroidism, hypogonadism)	+/-	-	0,2-0,6; suppressed LH, high normal DHEA-s	ED, headache, variability of blood pressure

Immuno-staining, women	Ki-67, %	n	Patient Age	Invasive	Giant	Cystic	Extension	Repeat surgery	Apoplexy	Visual Disturbances	Panhypopituitarism	PRL	Functional	LH/FSH	Symptoms
FSH, FSH-LH	1-5	6	37-64	100%	1 (16%)	-	CS, suprasellar cisterns, third ventricle	1 (16%)	1 (16%)	4 (67%)	1 (16%)	N	1	0,2-0,3	Menstrual irregularities, amenorrhea, obesity, hyperglycemia (non-functional), 1 breast Ca, nodular goiter
SF1	4-8	4	33-71	3 (75%)	-	-	CS, supra-infra	2 (50%)	1 (25%)	2 (50%)	1 (25%)	+/-	-	0,3-0,4	Menstrual irregularities, obesity, arterial hypertension
LH	1	4	59-67	3 (75%)	-	2 (50%)	CS, supra-infra (cystic)	-	1 (25%)	3 (75%)	2 (in non-cystic)	N	-	0,3-0,4	1 history of amenorrhea for 39 years; hypertension 1- nephrectomy (Ca), 1 nodular goiter, obesity
LH	2	5	45-69	2 (40%)	-	2 (40%)	supra-infra, CS	1 (20%)	-	3 (60%)	2 (40%)	elevated	3	0,02-0,2	Menorrhagia, cystic ovary, loss of pregnancy, amenorrhea, obesity -2
LH	3-4	7	35-68	3 (43%)	2 (28%)	1 (14%)	1 occlusive hydrocephalus	1 (14%)	-	5 (71%)	2 (28%)	Elevated in non-hypopituit.	+/-	0,02-1,01	Amenorrhea, weight loss, breast fibroadenoma, Ca ovary
LH	5-6	7	39-69	5 (71%)	3 (43%)	-	Supra-retro, CS	3 (43%)	-	100%	2 (28%)	Elevated when normal or elevated DHEA-s	-	0,2-0,5	Amenorrhea, flushes, obesity
LH, FSH	1	9	46-70	3 (33%)	1 (11%)	-	supra-infra, CS	1 (11%)	2 (22%)	6 (67%)	1 (11%)	+/-	-	0,2-0,3	Severe arterial hypertension, weight gain
LH, FSH	2-10	6	43-69	4 (67%)	3 (50%)	1 (17%)	1 occlusive hydrocephalus	1 (17%)	1 (17%)	5 (83%)	2 (33%)	elevated	+/-	0,12-0,19	Breast adenomas, amenorrhea, weight gain, diabetes mellitus



Conclusions. The differences in clinical presentation of gonadotroph adenomas revealed in our study depend on patient's age, sex and immunohistochemical staining. Precise clinical evaluation should be performed in patients with silent pituitary adenomas.